

The Mini-Arthrotomy Ankle Arthrodesis: A Review of Nine Cases

Philip Wroslavsky, DPM,¹ Renato Giorgini, DPM,² Christopher Japour, DPM,³ and Jacquelin Emmanuel, MD⁴

The authors report on the retrospective follow-up of 9 patients (6 women and 3 men) who underwent a mini-arthrotomy ankle arthrodesis by means of small incisions for exposure, cartilage resection, and internal fixation with crossed interfragmental compression screws. Patients were kept non-weight-bearing in a short leg cast for 12 weeks postoperative. At a mean follow-up of 55 months, outcomes were assessed by clinical examination, radiographs, and patient satisfaction questionnaires. Fusion was obtained in all patients, and there were no cases of delayed union, infection, or cutaneous compromise. Modified American Orthopaedic Foot and Ankle Society ankle and hindfoot rating scale scores significantly improved ($P < .001$) from a mean of 38 points preoperatively to 72 points at follow-up. A categorical assessment of functional ability in the postoperative period revealed 6 patients graded as excellent, 2 as good, and 1 as fair. In regard to a categorical assessment of clinical outcome in the postoperative period, 7 patients were graded as excellent and 2 as good. All of the patients stated that they were satisfied with their results and would undergo the procedure again. The mini-arthrotomy ankle arthrodesis with crossed interfragmental compression screw fixation appears to be a useful alternative to traditional open arthrodesis for selected patients with ankle arthritis. (The Journal of Foot & Ankle Surgery 45(6):424–430, 2006)

Key Words: ankle arthrodesis, mini-arthrotomy

Introduction

Ankle arthrodesis is a surgical procedure designed to induce bony ankylosis of a diseased ankle joint, and is indicated for treatment of a variety of degenerative and neuromuscular foot disorders. Since 1879, when Albert first published a paper describing ankle arthrodesis, a variety of surgical approaches, resection methods, and fixation techniques have been described for ankle fusion (1–5). It has been hypothesized that the wide variety of procedures used to achieve surgical fusion of the ankle may reflect the difficulty in fusing the small contact area between the talus and the tibia, because this interface is subject to high stresses related to the long lever arms of the foot and tibia (6–10). Historically, percutaneous methods of fusion, with partial or total preservation of the preoperative ankle con-

tour, have been described in the literature (9–14); including dowel arthrodesis (11), arthroscopy-assisted arthrodesis (13), and the mini-arthrotomy approach (14). Turan (15) states that the mini-arthrotomy ankle arthrodesis reduces morbidity in high-risk patients and allows for a more rapid return to normal activity in young patients (5, 16). The mini-arthrotomy uses a percutaneous approach technique through which the synovial membrane, hyaline cartilage, and subchondral bone are denuded from the talotibial interface while preserving the configuration of the ankle mortise (17–19). This approach to ankle arthrodesis is generally carried out with small, approximately 2 cm in length, incisions localized to the anteromedial and anterolateral aspects of the ankle; and the overall preoperative contour of the ankle is maintained. Therefore, it is important that the preoperative ankle alignment not be severely deformed when the mini-arthrotomy method is used. Ideally, the postoperative orientation of the ankle should entail approximately 0° flexion, 0° to 5° hindfoot valgus, and 5° to 10° external rotation. Moreover, with this technique, corrective osteotomy and bone grafting are generally not used.

The purpose of this study was to retrospectively evaluate the clinical and radiographic outcomes of 9 patients who had undergone percutaneous mini-arthrotomy ankle arthrodesis with crossed interfragmental lag screw fixation. We

¹From the North General Hospital, New York, NY, USA; ²North General Hospital, New York, NY, USA; ³Danville Veterans Administration, Department of Surgery (112), Danville, IL; ⁴North General Hospital, New York, NY, USA.

Address correspondence to: Dr. Philip Wroslavsky, North General Hospital, Surgery, 1879 Madison Ave, New York, NY 10035. E-mail: drphilipw@msn.com

Copyright © 2006 by the American College of Foot and Ankle Surgeons
1067-2516/06/4506-0010\$32.00/0
doi:10.1053/j.jfas.2006.09.006

also attempt to show that satisfactory fusion can be obtained despite leaving the posterior third of the talar cartilage intact. This practice is contrary to the belief that fusion can occur on broad, flat cancellous surfaces placed in apposition to each other (20, 21).

Materials and Methods

Nine patients underwent ankle arthrodesis using a mini-arthrotomy approach. All of the procedures were performed by the authors at a single institution between March 1998 and December 2001. All of the patients had a diagnosis of posttraumatic arthritis with minimal or no gross deformity of the ankle, and all had severe functional impairment that included the inability to ambulate in a weight-bearing fashion without pain. All of the patients described severe weight-bearing pain as the primary reason for choosing to undergo the procedure. They were unable to walk more than 2 blocks or up a flight of stairs without severe pain. Ankle range of motion was painful, limited, and crepitant. There were no significant angular deformities such as varus, valgus, or recurvatum of the affected ankles. All preoperative radiographs exhibited subchondral sclerosis, joint-space narrowing, and joint destruction of the ankle. Conservative measures such as nonsteroidal anti-inflammatory and analgesic medications, special footwear, or orthotic devices provided no relief (Figs 1 and 2).

Preoperative and postoperative patient assessments were evaluated based on each patient's medical record, clinical evaluation, and patient interview. When patients returned for follow-up evaluation, they were questioned regarding the severity and location of any ankle pain, the distance that they were able to walk, the type of shoes that they usually wore, their ability to walk up and down stairs, their ability to run and participate in recreational activities, their current employment status, and whether they were satisfied with the result of the arthrodesis surgery. To assess union of the arthrodesis site, standard standing anteroposterior (AP) long leg radiographs, standing AP and lateral radiographs of the ankle, and AP and lateral radiographs of the foot were performed on each patient at the time of final follow-up.

The surgical outcome was assessed with the numeric American Orthopaedic Foot and Ankle Society's (AOFAS) Ankle-Hindfoot rating system. The AOFAS scale is a numerical rating system designed to grade the ankle with regard to pain (40 points), function (50 points), and range of motion (10 points). Part of our clinical outcome measurements were obtained by means of the AOFAS ankle score, modified by eliminating the range-of-motion component. Because one domain of the AOFAS rating system assesses range of motion, diminishing the value of the system for this study of arthrodesis effects, patients were also evaluated with a non-numeric rating system developed by Paley (22).

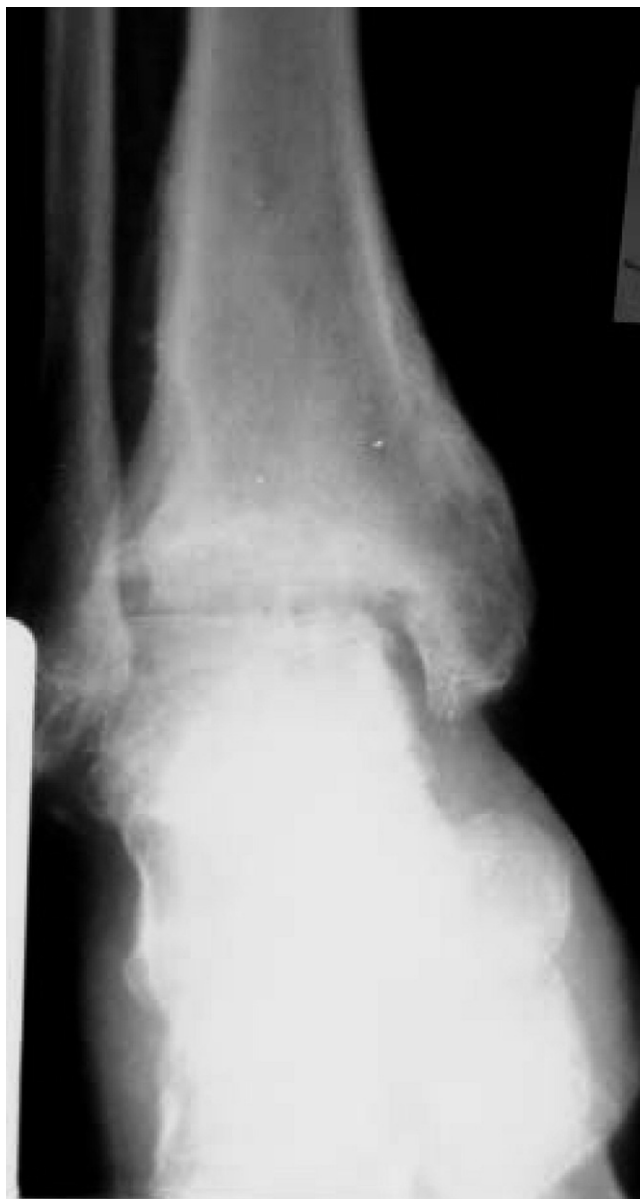

FIGURE 1 Typical pre-operative ankle anterior-posterior weight-bearing x-ray.

This scale is divided into clinical and functional outcome components. Outcomes were evaluated for each patient on a scale described by the authors as excellent, good, fair, or poor. Clinical outcomes were based on the presence or absence of union, infection, deformity, and limb-length discrepancy. The criteria for solid union included a clinically stable ankle that was pain free with manipulation and weight-bearing, as well as radiographic evidence of trabeculae bridging the fusion interface without a change in the position of the ankle. The postoperative clinical outcome was considered to be excellent when there was solid arthrodesis, no sign of infection, a neutral or slight calcaneus

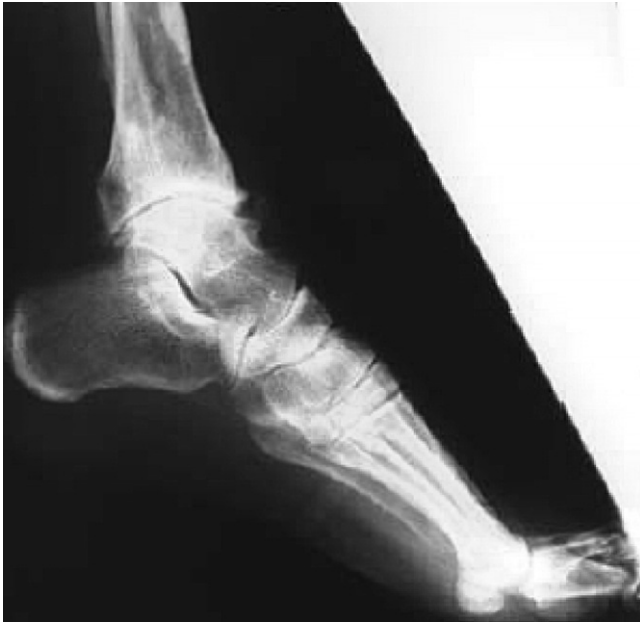

FIGURE 2 Typical pre-operative ankle lateral weightbearing x-ray.

position ($\leq 5^\circ$ of dorsiflexion), neutral to 5° of valgus, external rotation of 0° to 15° , neutral or slight posterior translation of the talus on the tibia, and a limb-length discrepancy of ≤ 1.5 cm due to shortening of the operated lower extremity. The clinical outcome was considered to be good when there was solid union without infection; slight equinus ($\leq 5^\circ$ of plantar flexion), 5° to 10° of valgus or varus, $\leq 5^\circ$ of internal rotation, or ≤ 1 cm of anterior translation; and a limb-length discrepancy of ≤ 3 cm. The clinical outcome was considered to be fair when there was union without infection; 5° to 10° of plantarflexion or dorsiflexion, 5° to 10° varus or $>10^\circ$ of valgus, internal rotation of the foot $> 5^\circ$, anterior translation of >1 cm, or moderate forefoot deformity; and limb-length discrepancy of >3 cm. If the nonunion, infection, or malunion remained equal to or worse than the preoperative condition, the clinical outcome was considered to be poor.

The functional outcome was based on 4 criteria: pain, gait abnormality, daily activities, and walking distance. The functional outcome was considered to be excellent if the patient had no pain, had no gross limp or only a slight limp, was able to perform activities of daily living, and was able to walk for more than 6 blocks without any difficulty or pain. The functional outcome was considered to be good if the person had mild pain necessitating only occasional analgesics, had a mild gait abnormality, was able to perform activities of daily living, and was able to walk for 3 to 6 blocks without any difficulty or pain. The functional outcome was considered to be fair if the person had pain that necessitated regular analgesic use, displayed an overtly an-

talgiic gait, was inhibited from doing any of the activities of daily living, and was unable to walk more than 3 blocks because of ankle pain. If a patient had constant pain, a constant antalgic gait and was unable to walk more than a few steps, and was inhibited from doing any of the activities of daily living, then the functional outcome was considered to be poor.

Surgical Technique

The patient was positioned supine on the operating table, and a midcalf tourniquet was used to aid hemostasis. Anterolateral and anteromedial incisions, approximately 2 cm in length, were made over the medial and lateral gutters of the ankle joint. Capsulotomy was then performed to expose the ankle mortise so that direct visual inspection could be made, and the gross articular changes consistent with traumatic arthritis of the talar dome and the medial and lateral mortise gutters were identified. No distraction devices were used to aid inspection or subsequent resection of the articular surfaces. The joint surfaces were then denuded of cartilage and subchondral cortical bone with a manual curettage method that preserved the general shape of the ankle mortise. The cartilage of approximately the posterior third of the talus was left intact, while that of the entire distal tibial-bearing surface was denuded of cartilage and subchondral cortical bone. The joint cavity was then flushed with copious amounts of saline solution in an effort to remove any free-floating fragments of cartilage and cortical bone. The foot was then placed in the position of desired fusion, specifically a neutral sagittal plane position with slight frontal plane valgus and slight transverse plane external rotation. Thereafter, using fluoroscopic image intensification, two 7.0-mm diameter, 16-mm thread-length pattern, cannulated interfragmental compression screws (Zimmer Corp, Warsaw, IN) were percutaneously positioned across the talotibial arthrodesis interface, using separate incisions from those used for joint resection. The first screw was placed from the distal third of the fibula across the ankle joint into the body of the talus, and the second screw was placed through the distal-lateral surface of the tibia into the talar dome and also seated into the talar body (Figs 3–6). Fluoroscopic inspection also assured that all of the screw threads of each screw had passed the distal-bearing surface of the tibia, and were seated in the body of the talus without violation of the posterior talocalcaneal joint. The foot was then put through a range-of-motion assessment to ensure the presence of motion in the subtalar joint but not at the level of the fixated ankle. The pneumatic tourniquet was deflated before layer closure. After ankle capsular, and subcutaneous layer and skin closure, all of the patients were kept in a non-weight-bearing short leg cast for approximately 12 weeks. Thereafter, in accordance with

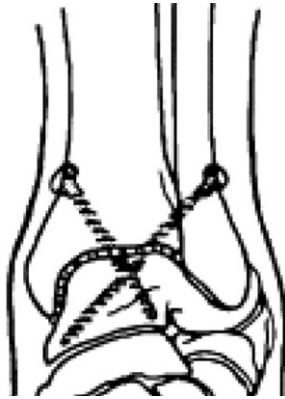


FIGURE 3 Illustration, anterior-posterior view of ankle anterior-posterior weightbearing x-ray with two crossed fixation compression screws.

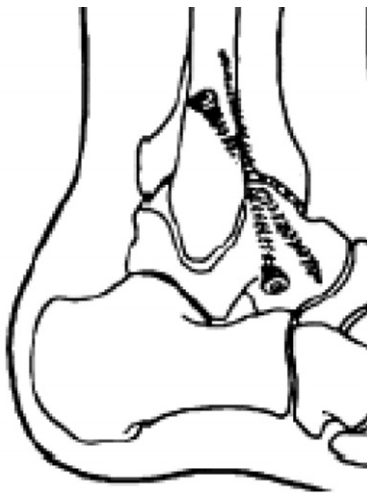

FIGURE 4 Illustration, lateral view of ankle anterior-posterior weightbearing x-ray with two crossed fixation compression screws.

clinical and radiographic progress, the patients returned to normal shoe gear with use of a custom solid ankle-foot orthosis for approximately 3 months.

Results

This study included 9 patients, 6 women and 3 men, displaying a mean average age of 50 years (range, 43–57 years). The patients were followed up for a mean average of 55 months postoperatively (range, 17–71 months). The mean duration of symptoms preoperatively was 5 years (range, 4–5 years). All 9 of the patients achieved a solid arthrodesis, and they all stated that they were satisfied with the outcome of the surgery and would undergo it again. Seven patients related no pain in the postoperative period after identification of radiographic evidence of solid fusion, whereas 2 patients reported occasional, mild pain that necessitated the use of analgesics. Analysis of

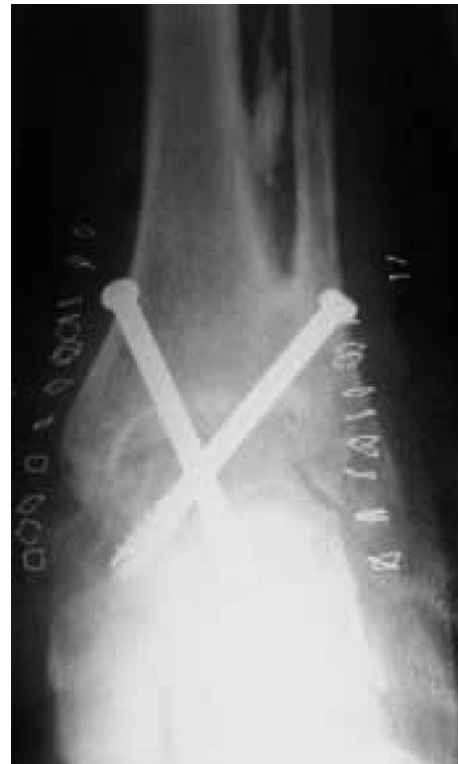

FIGURE 5 Anterior-posterior weightbearing ankle x-ray, immediate post operative film.

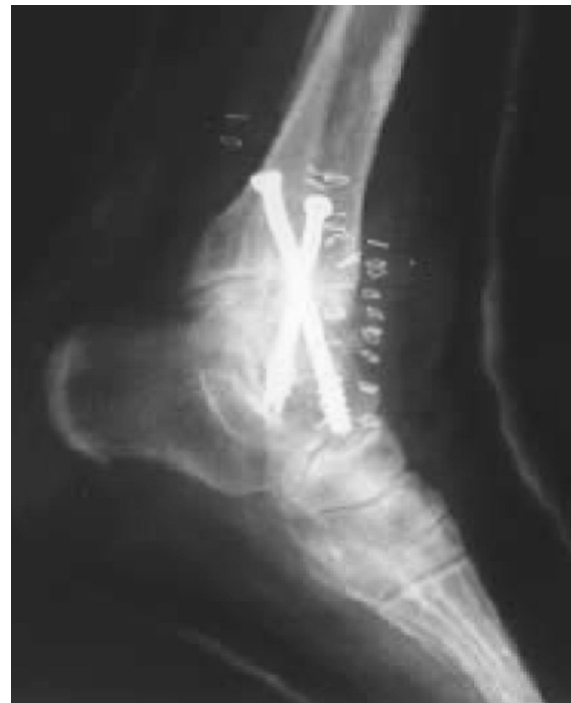

FIGURE 6 Lateral weightbearing ankle x-ray, immediate post operative film.

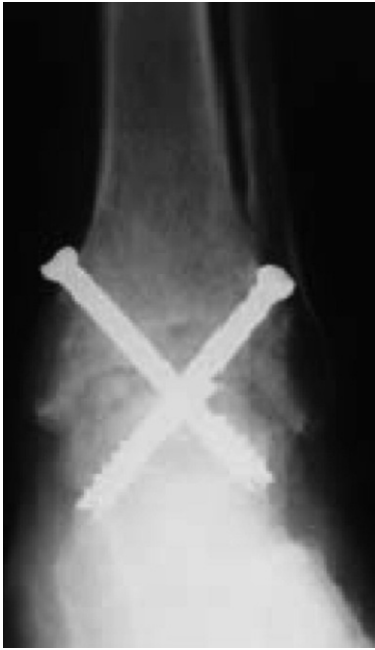

FIGURE 7 Anterior-posterior ankle weightbearing x-ray, 3 months post operative film.

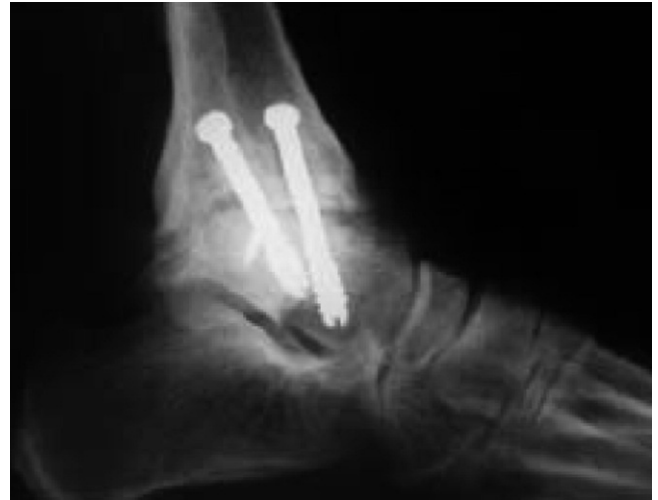

FIGURE 9 Lateral ankle weightbearing x-ray, 3 months post operative film.

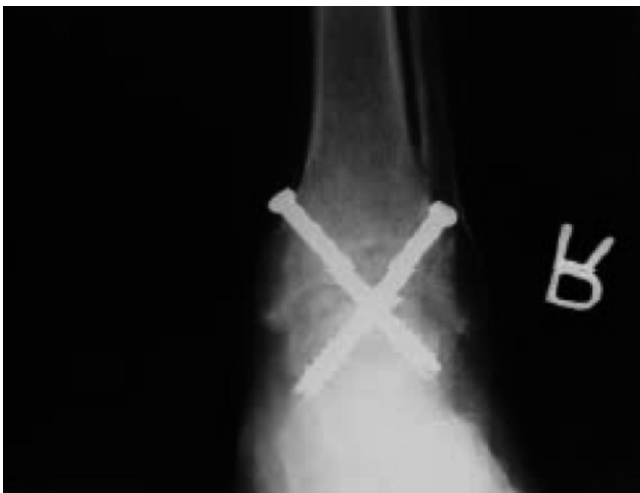

FIGURE 8 Anterior-posterior ankle weightbearing x-ray, 6 months post operative film.

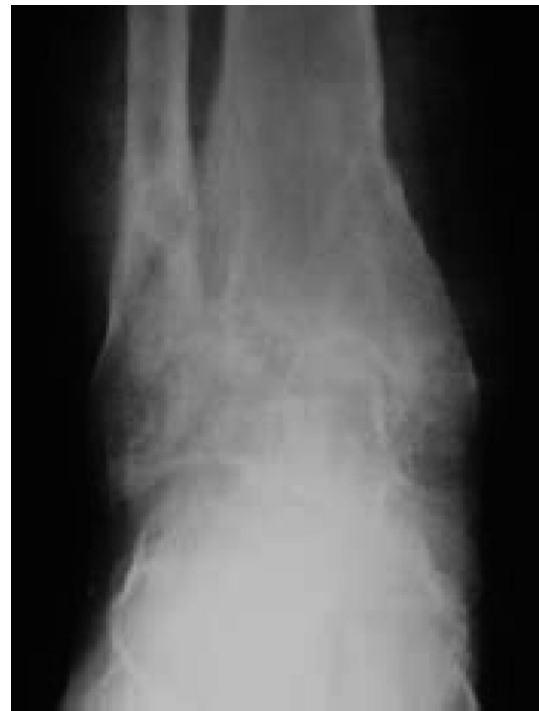

FIGURE 10 Anterior-posterior ankle weightbearing x-ray, 36 months post operative film.

the AOFAS rating scale (Student *t*-test) demonstrated a significant ($P < .001$) difference between the mean preoperative score of 38 points (range, 33–45) and the mean postoperative score of 72 points (range, 65–78). Six patients demonstrated an excellent functional result, 2 had a good result, and 1 patient exhibited a fair result. Seven patients demonstrated an excellent clinical outcome and 2 had a good clinical outcome. At the time of final follow-up, all 9 patients presented wearing regular shoes and 6 wore shoes with an ankle-foot orthosis. All

patients were able to walk without pain for more than 6 blocks. One patient who had subsequent gouty arthritis was unable to walk without the use of a cane. Two patients had symptoms related to screw head prominence 3 years after the surgery, necessitating a return to the operating room for removal of the screws on an outpatient basis (Figs 7–11) (Table 1).

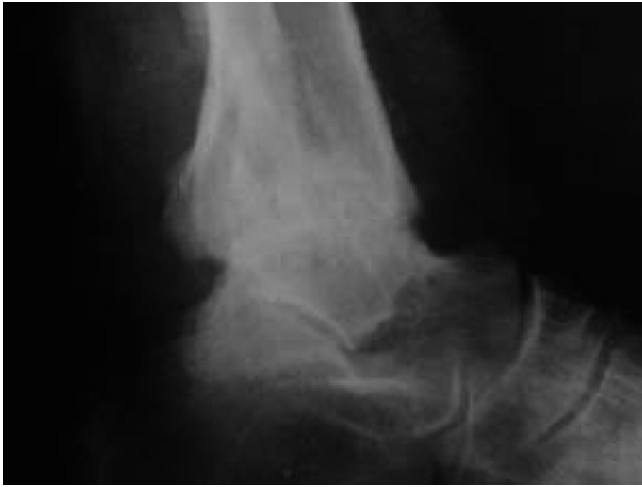

FIGURE 11 Lateral ankle weightbearing x-ray, 36 months post operative film.

Discussion

The mini-arthrotomy ankle arthrodesis is less invasive than more traditional open techniques of ankle fusion, and allows for less formation of visible cutaneous scar tissue. Severe angular deformity is a contraindication to this approach, because wedging and the use of osteotomy to realign the ankle before arthrodesis are made difficult by the limited exposure. The surgical technique used in this study involves manual removal of the articular cartilage and subchondral bone cortex, rather than the use of power instrumentation and, theoretically, diminishes the risk of thermal necrosis of viable cells at the level of bone resection. Moreover, the relatively short operative time, reduced amount of dissection, shorter tourniquet time, and less blood loss reduce the degree of morbidity associated with this method of ankle fusion and eliminate the need for hospitalization in most cases. In turn, use of the mini-arthrotomy ankle arthrodesis as described in this investigation avoids the use of the arthroscope and, by reducing morbidity, is thereby likely to diminish the overall cost of ankle arthrodesis.

This technique raises the question as to how fusion can be obtained without, by design, removing all of the cartilage from the posterior third of the body of the talus and without creating broad, flat cancellous bone surfaces that are placed into apposition with each other. We theorize that, with the mini-arthrotomy technique described herein, the mechanism of fusion may be enhanced by depletion of the synovial fluid as a result of debridement of the synovial surface of the ankle joint capsule, in the presence of stable interfragmental compression. We believe that depletion of the synovial fluid destroys chondrocytes in the area of the tibiotalar fusion interface, and that this leads to rapid degeneration of cartilage matrix and decreases the likelihood of the development of a fibrocartilaginous non-union. In the presence of stable bone fixation, bone growth

across the arthrodesis occurs by means of creeping substitution, and remodeling continues for many months after the operation. Furthermore, we have observed that a satisfactory and functional arthrodesis can take place even when radiographic evidence indicates that the posterior third of the talar dome fails to display trabecular bridging with the tibia. In essence, we feel that radiographic evidence of trabecular bridging across the entire tibiotalar interface is not essential for satisfactory fusion and a pain-free result. Still further, a strong subchondral bone surface area also contributes to the stability of this arthrodesis technique. These concepts related to arthrodesis were tested in Lauge-Pedersen et al's studies (23–28), in which they fused rabbit joints with percutaneous fixation. They felt that depletion of the synovial fluid was an important factor related to the degeneration of cartilage and the progression of trabecular bridging. The sloping contour of the posterior aspect of the dome of the talus poses an inherent difficulty in regard to denuding the entirety of its cartilage and subchondral bone. However, we feel this shortcoming is overcome, and satisfactory arthrodesis can be achieved when synovial fluid is diminished and the arthrodesis interface is compressed and maintained in a stable alignment. These conditions promote degeneration of the cartilage remaining on the posterior third of the talus, and favor arthrodesis without fibrous union. In fact, the authors of this study believe that Lauge-Pedersen et al's studies and concepts regarding arthrodesis do not receive enough recognition among surgeons, and that, when applied correctly, these concepts can increase the union rate among patients undergoing arthrodesis not only of the ankle but of other joints as well. Our retrospective evaluation of patients undergoing mini-arthrotomy conveys a number of limitations. The outcome instruments used in this investigation were considered to be biased assessment tools that have not been tested for reliability and validity in the format used in this study. The "modified" AOFAS scoring scale weights motion rather importantly; however, planned fusion eliminates motion, and, therefore, the scoring scale may not be the best assessment tool for this particular outcome. Understanding this limitation, we also looked at a categorical rating scale for clinical and functional outcomes; however, these instruments, too, were not tested for reliability or validity, although we feel that they convey face validity in light of the intervention and our desired outcomes. They were, moreover, biased toward a more favorable assessment. We also used unblinded assessment of the radiographic outcome, particularly in regard to the time to fusion, and this also imparts considerable bias, because the assessors were also the surgeons. Computerized tomograms may have yielded a more reliable assessment of this particular outcome. In regard to the intervention, it would be possible to introduce demineralized bone matrix to the arthrodesis interface, and this may affect the time to fusion in comparison with the results of this study. Still further, in the future, it would be interesting to compare the results of this intervention with those of arthroscopic ankle arthrodesis.

TABLE 1

Gender	Age (at time of sx)	Significant history	Significant prior treatment/years ago	Surgery time/min	Type of anesthesia	AOFAS score preop/postop	Clinical score	Functional score
Male	55		ORIF/5	50	Local/MAC	33/74	Good	Excellent
Female	57	HTN	ORIF/4	60	Local/MAC	35/78	Excellent	Excellent
Male	45		ORIF/5	60	Local/MAC	42/68	Excellent	Good
Female	43	Hepatitis C	ORIF/5	60	Local/MAC	35/70	Excellent	Excellent
Female	56	Gout	ORIF/5	60	Local/MAC	33/65	Excellent	Fair
Male	53	Hepatitis C	ORIF/arthroscopy/4	60	Local/MAC	35/68	Excellent	Good
Female	44	Type II diabetes	ORIF/5	50	Local/MAC	41/70	Excellent	Excellent
Female	50	Type II diabetes	ORIF/5	45	Local/MAC	45/78	Good	Excellent
Female	47	HTN	ORIF/5	45	Local/MAC	42/76	Excellent	Excellent

Abbreviations: HTN, hypertension; ORIF, open reduction with internal fixation; MAC, monitored anesthesia care.

The limitations of this procedure include the need for experience with ankle arthrodesis and its operative techniques. Also, if technical difficulties arise during the procedure, the surgeon should be prepared to convert to a standard open approach, and, in the preoperative setting, this possibility should be discussed with the patient. With respect to study design, future investigations with larger sample sizes and longer follow-up periods would be helpful in determining if the high rate of fusion and the low rate of complications observed in this investigation would bear out. Indeed, we feel that the satisfactory clinical and functional outcomes experienced by the patients in this study suggest that the mini-arthrotomy ankle arthrodesis with percutaneous lag screw placement is a viable alternative to traditional open approaches to ankle arthrodesis in selected patients with disabling ankle arthritis and minimal deformity.

References

- Albert E. Beitrage zur operativen Chirurgie. Zur resection des kniegeelenkes. Wien Med Press, 20:705–708, 1879.
- Morgan CD, Henke JA, Baily RW. Long-term results of tibiotalar arthrodesis. *J Bone Joint Surg* 67A:546–550, 1985.
- Morrey BF, Wiedman GP Jr. Complications and longterm results of ankle arthrodesis following trauma. *J Bone Joint Surg* 62A:777–784, 1980.
- Chamley J. Compression arthrodesis of the ankle and shoulder. *J Bone Joint Surg* 33B:180–191, 1951.
- Easley ME, Vertullo CJ, Urban WC. Total ankle arthroplasty. *J Am Acad Orthop Surg* 10:157–167, 2002.
- Saltzman CL, McIff TE, Buckwalter JA. Total ankle replacement revisited. *J Orthop Sports Phys Ther* 30:56–67, 2000.
- Belt EA, Maenpaa H, Lehto M. Outcome of ankle arthrodesis performed by dowel technique in patients with rheumatic disease. *Foot Ankle Int* 22:666–669, 2001.
- Baciu CC. A simple technique for arthrodesis of the ankle. *J Bone Joint Surg* 68:266–267, 1986.
- Cameron SE, Ullrich P. Arthroscopic arthrodesis of the ankle joint. *Arthroscopy* 16:21–26, 2000.
- Jerosch J, Steinbeck J, Schroder M. Arthroscopically assisted arthrodesis of the ankle joint. *Arthroscopy* 16:21–26, 2000.

- Ottolenghi CE, Animoso J, Burgo PH. Percutaneous arthrodesis of the ankle joint. *Clin Orthop* 68:72–74, 1970.
- Stranks GJ, Cecil T, Jeffrey IT. Anterior ankle arthrodesis with cross-screw fixation: a dowel graft method used in 20 cases. *J Bone Joint Surg* 76B:943–946, 1994.
- Katcherian DA. Treatment of ankle arthrosis. *Clin Orthop* 349:48–57, 1998.
- Hefti FL, Baumann JU, Morscher EW. Ankle joint fusion: determination of optimal position by gait analysis. *Arch Orthop Trauma Surg* 96:187, 1980.
- Turan I, Blumgren G. Ankle arthrodesis by the Heiple technique in rheumatoid arthritis. *J Foot Surg* 30:143–146, 1991.
- Turan I, Wredmark T, Fellander-Tsai L. Arthroscopic ankle arthrodesis in rheumatoid arthritis. *Clin Orthop* 320:110–114, 1995.
- Paremain GP, Miller SD, Myerson MS. Ankle arthrodesis: results after miniarthrotomy technique. *Foot Ankle Int* 17:147–152, 1996.
- Miller SD, Myerson MS. Tibiotalar arthrodesis. *Foot Ankle Clin* 1:151–161, 1996.
- Myerson MS, Quill G. Ankle arthrodesis: a comparison of an arthroscopic and an open method of treatment. *Clin Orthop* 268:84–95, 1991.
- Pickering RM. Arthrodesis of ankle, knee, and hip. In *Campbell's Operative Orthopaedics*, pp 156, edited by ST Canale, Mosby, St. Louis, 2003.
- Ferkel RD, Hewitt M. Long-term results of arthroscopic ankle arthrodesis. *Foot Ankle Int* 26:275–279, 2005.
- Paley D. The correction of complex foot deformities using Ilizarov's distraction osteotomies. *Clin Orthop* 293:97–111, 1993.
- Lauge-Pedersen H, Aspenberg P. Arthrodesis by percutaneous fixation: patellofemoral arthrodesis in rabbits without debridement of the joint. *Acta Orthop Scand* 73A:186–189, 2002.
- Lauge-Pedersen H, Aspenberg P. Synovial fluid depletion may explain successful arthrodesis without operative cartilage removal. *J Orthop Sci* 8:591–595, 2003.
- Lauge-Pedersen H, Aspenberg P, Ryd L. Arch-shaped versus flat arthrodesis of the ankle joint: strength measurements using synthetic cancellous bone. *Proc Inst Mech Eng [H]* 216B:43–49, 2002.
- Lauge-Pedersen H, Knutson K, Rydholm U. Percutaneous ankle arthrodesis in the rheumatoid patient without debridement of the joint. *Foot* 8A:226–229, 1998.
- Lauge-Pedersen H. Percutaneous arthrodesis. *Acta Orthop Scand* 74(Suppl I):1–30, 2003.
- Lauge-Pedersen H, Odenbring S, Knutson K. High failure with the dowel technique for the fusion of rheumatoid ankles. *Foot* 8B:147–149, 1998.